

White Matter and Behavioral Neurology

Christopher M. Filley, M.D.
Director, Behavioral Neurology Section
Professor of Neurology and Psychiatry
University of Colorado Denver School of Medicine
Denver Veterans Affairs Medical Center

Why White Matter Matters

(Filley CM. *The Behavioral Neurology of White Matter*,
Oxford University Press, 2001)

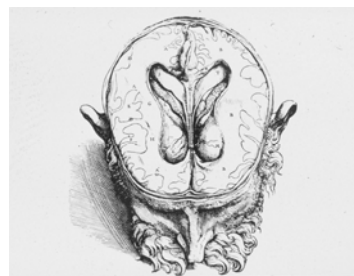
- Disorders of cerebral white matter affect people of all ages
- MRI readily detects these disorders
- There are more than 100 diseases, intoxications, and injuries in which cerebral white matter is prominently affected
- Although data are often scanty, review of clinical reports in these conditions *without exception* reveals some evidence of cognitive and/or emotional disturbance

Clinical Examples

- Up to 65% of patients with multiple sclerosis (MS), the best known central nervous system white matter disease, have cognitive impairment, and up to 23% have dementia at some point in the disease course
- More than 1,000,000 Americans survive traumatic brain injury each year, and diffuse axonal injury in the white matter is likely present in every one of these individuals
- 20% of U.S. eighth-graders report use of inhalants, among which the white matter toxin toluene is the most common solvent

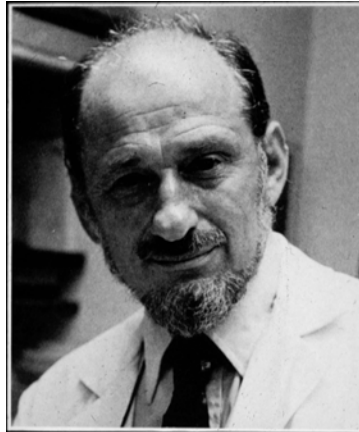
Early Anatomy

- White matter was not recognized by physicians of antiquity
- The anatomist Andreas Vesalius was the first to identify white matter in 1543
- In the seventh book of his masterwork, *De Humani Corporis Fabrica*, the white matter is clearly demarcated from the gray in drawings of the brain



The Beginning of the Modern Era

- Norman Geschwind (1926-1984), the leading behavioral neurologist of the 20th century, advanced the study of white matter with his ideas on disconnection
- His paper “Disconnexion Syndromes in Animals and Man” (1965) pointed out how lesions of white matter can disconnect cerebral areas and produce neurobehavioral syndromes



Distributed Neural Networks

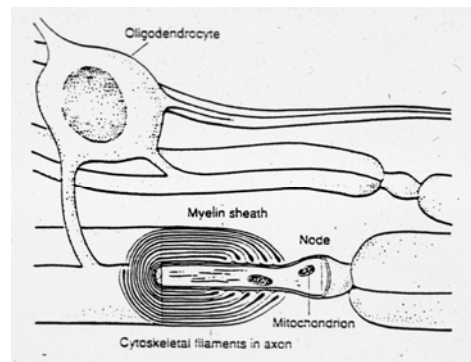
- The work of Geschwind was crucial in the development of thinking about distributed neural networks in the brain that subserve neurobehavioral functions
- M-Marsel Mesulam, one of Geschwind’s many colleagues, has put forth elegant models of brain structure and function in which white matter projections play a key role in brain connectivity

Basic Neuroscience of White Matter

- 40-50% of the adult brain volume is occupied by white matter
- White matter consists of myelinated axons, glial cells, and blood vessels
- There are ~ 85,000 miles of myelinated axons in the human cerebrum
- Efficient information transfer between brain regions is only possible through the normal function of white matter

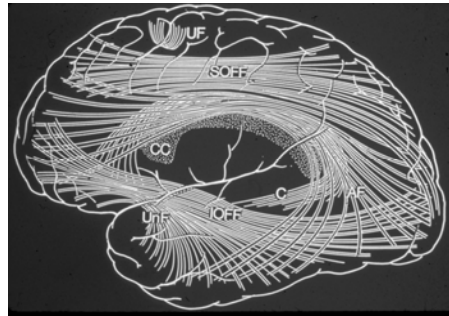
White Matter Structure: Microscopic Anatomy

- The myelin sheath wraps around axons, leaving small segments called nodes of Ranvier every 1-2 millimeters
- Myelin is about 70% lipid, 30% protein
- Oligodendrocytes are responsible for myelinating CNS axons



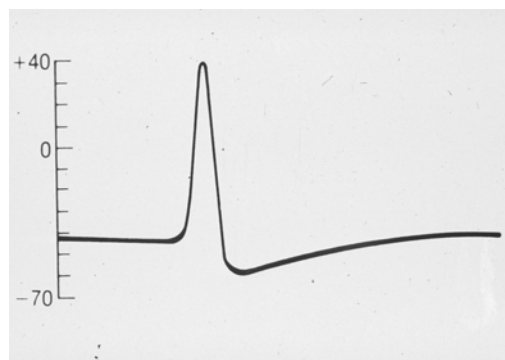
White Matter Structure: Gross Anatomy

- Millions of myelinated fibers coalesce into tracts, fascicles, funiculi, lemnisci, peduncles, and bundles
- Major tracts in the brain are divided into projection, commissural, and association fiber systems; the latter two are most important for neurobehavioral function



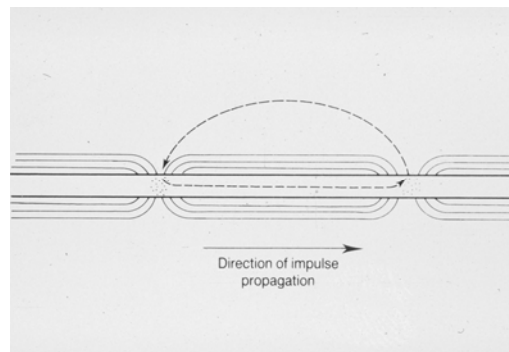
White Matter Function: Axonal Physiology

- Neurons normally act to propagate a nerve impulse called the action potential
- This “spike” is generated by the rapid influx of sodium ions that transiently reverses the polarity of the axonal membrane



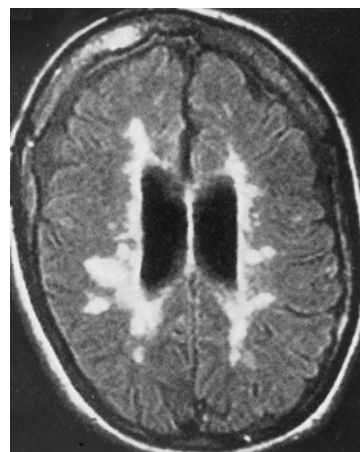
White Matter Function: Saltatory Conduction

- The myelin sheath permits the impulse to “jump” from one node of Ranvier to the next
- Large myelinated fibers conduct impulses about 100 times faster than small unmyelinated fibers



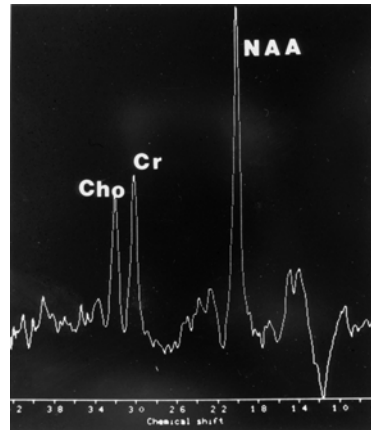
Magnetic Resonance Imaging

- White matter lesions can be well seen, particularly with fluid inversion recovery (FLAIR) images, as in this patient with MS
- Voxel-based morphometry (VBM) can be used to quantitate white matter lesions and volume



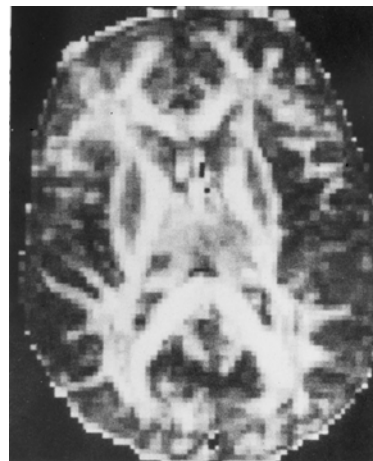
Magnetic Resonance Spectroscopy (MRS)

- This technique measures chemical concentrations within white matter and gray matter regions
- A “non-invasive biopsy”
- Decreased N-acetyl aspartate (NAA) implies axonal damage; increased choline (Cho) implies demyelination and inflammation



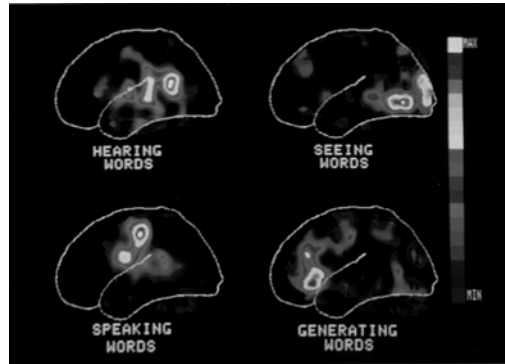Diffusion Tensor Imaging (DTI)

- This technique permits measurement of the directionality of water diffusion in the brain
- White matter tractography can identify individual tracts
- Reduced fractional anisotropy (FA) signifies microstructural white matter injury



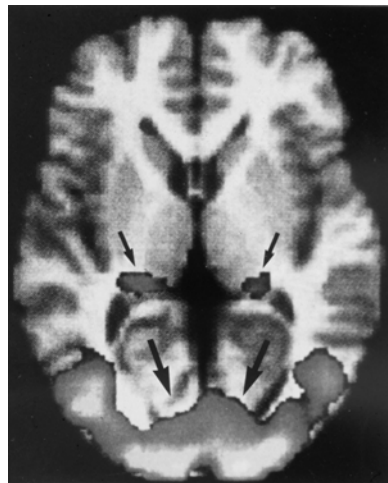Positron Emission Tomography (PET)

- One of the major techniques used to conduct functional neuroimaging
- Cortical metabolism is quantitated while a subject performs a cognitive task



Functional MRI (fMRI)

- The newest of the evolving functional neuroimaging techniques
- fMRI quantitates brain activity by means of measuring oxygen utilization in metabolically active regions



Mapping Neural Networks

- The combination of structural and functional neuroimaging holds promise for mapping out distributed neural networks
- Thus DTI and MRS can identify and characterize the white matter tracts that provide the neuroanatomic connectivity between the gray matter structures identified by PET and fMRI

White Matter Disorders

- Genetic
- Demyelinative
- Infectious
- Inflammatory
- Toxic
- Metabolic
- Vascular
- Traumatic
- Neoplastic
- Hydrocephalic

Lessons Learned

- White matter is usually damaged in a diffuse pattern, and isolated, discrete lesions of white matter are uncommon
- Knowledge of the tract(s) affected is not precise or detailed
- Normal-appearing white matter may not be normal, so analysis of correlations between lesions and behavior becomes complex
- Most white matter disorders also involve at least some gray matter damage

Neurobehavioral Aspects of White Matter Disorders

Three major categories:

1. Focal neurobehavioral syndromes
2. Neuropsychiatric syndromes
3. Cognitive dysfunction and dementia

Focal Neurobehavioral Syndromes

Amnesia	Alexia
Aphasia	<i>Pure alexia</i>
<i>Broca's</i>	<i>Alexia with agraphia</i>
<i>Wernicke's</i>	Developmental dyslexia
<i>Conduction</i>	Gerstmann's syndrome
<i>Global</i>	Agnosia
<i>Transcortical motor</i>	<i>Visual</i>
<i>Transcortical sensory</i>	<i>Auditory</i>
<i>Anomic</i>	Neglect
<i>Mixed transcortical</i>	Visuospatial dysfunction
Apraxia	Akinetic mutism
<i>Ideomotor</i>	Executive dysfunction
<i>Callosal</i>	Callosal disconnection

Neuropsychiatric Syndromes

Psychiatric Syndromes in White Matter Disorders	Psychiatric Disorders with White Matter Abnormalities
<i>Depression</i>	<i>Schizophrenia</i>
<i>Mania</i>	<i>Depression</i>
<i>Psychosis</i>	<i>Bipolar disorder</i>
<i>Pathologic affect</i>	<i>ADHD</i>
<i>Euphoria</i>	<i>Autism</i>
<i>Fatigue</i>	<i>Aggression</i>

White Matter Dementia

(Filley et al., *Neuropsychiatry Neuropsychol Behav Neurol* 1988; 1: 239-254)

- Dementia resulting from damaged cerebral white matter
- The white matter disorders include a wide range of neuropathological disturbances, but their common feature is disruption of myelinated systems in the brain
- Originally listed under the heading of subcortical dementias, the white matter disorders manifest unique neurobehavioral features that justify a separate category

How Many Cases Are Being Missed?

- White matter disorders are not rare, and medical literature and clinical experience suggest that cognitive dysfunction, often sufficient to meet criteria for dementia, is the most common neurobehavioral syndrome
- However, cognitive dysfunction, and even dementia, may be overlooked because attention is devoted to other neurologic sequelae of white matter dysfunction such as blindness, paralysis, or incontinence

The Clinical Profile of White Matter Dementia

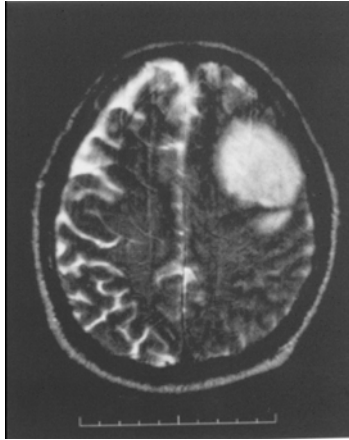
- Sustained attention deficit
- Executive dysfunction
- Memory retrieval deficit
- Normal procedural memory
- Relatively preserved language
- Visuospatial impairment
- Psychiatric disorder
- Normal extrapyramidal function

Toxic Leukoencephalopathy

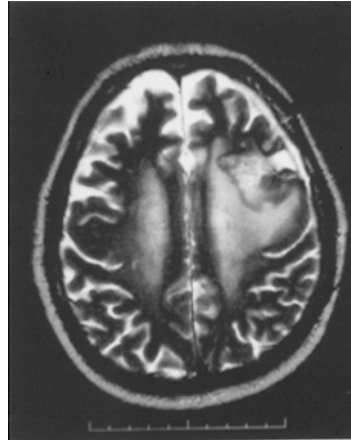
(Filley & Kleinschmidt-DeMasters,
N Engl J Med 2003; 345: 425-432)

- A toxic disorder of brain white matter
- Diffuse white matter damage is typical
- Neurobehavioral dysfunction is the most important clinical manifestation
- Three categories: therapeutic agents (e.g. radiation), drugs of abuse (e.g. toluene), environmental toxins (e.g. carbon monoxide)

Radiation Leukoencephalopathy: MRI




Glioma pre-radiation




Glioma post-radiation

Radiation Leukoencephalopathy: Neuropathology



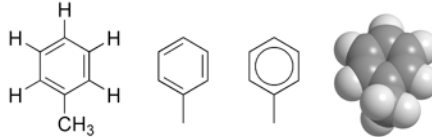
Normal myelin (H&E)



Post-radiation myelin

Toluene and Toluene Abuse

- Toluene is a widely used industrial and household solvent
- Inhalation of toluene vapors is a common form of substance abuse

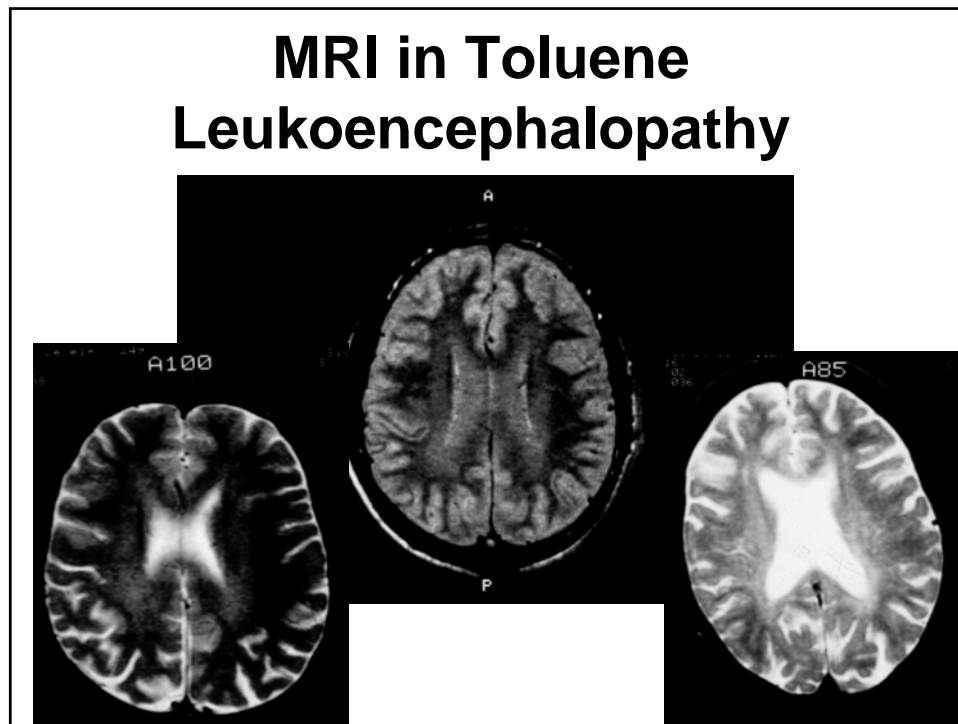


- The major solvent in spray paint, which is legal and inexpensive
- “Huffing” or “bagging” spray paint is preferred by many adolescents and young adults

Toluene Leukoencephalopathy

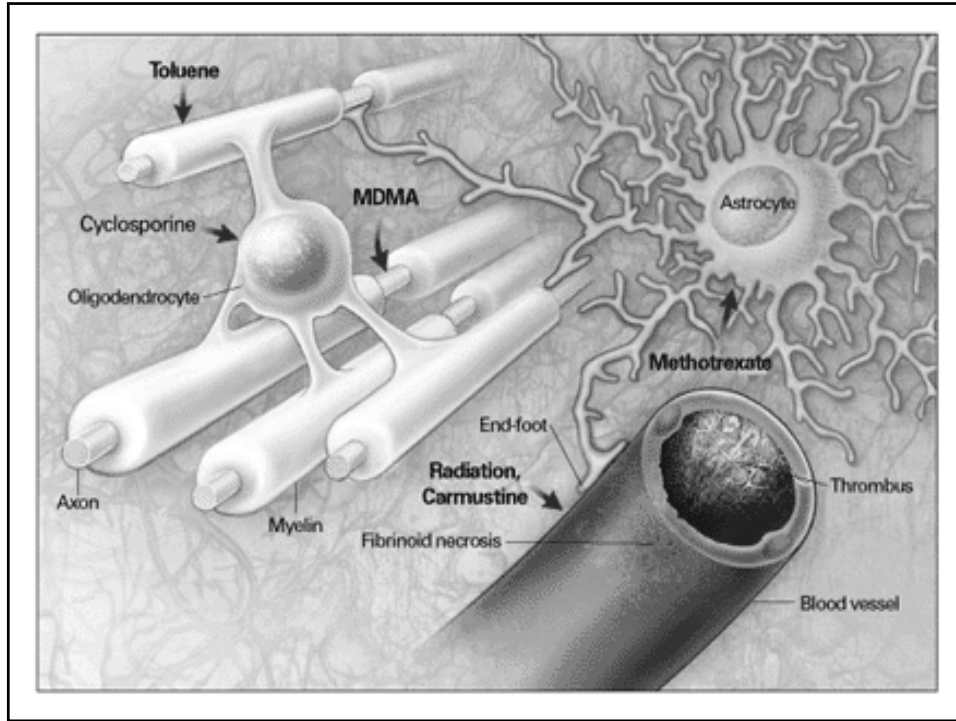
(Filley et al., Neurology 1990; 40: 532-534)

- We studied 14 toluene abusers (10M/4F, age 20-43), who had between 24 and 252 months of heavy toluene exposure
- MRI and comprehensive neuropsychological data were analyzed blindly and then compared
- Longer duration of toluene abuse predicted more severe MRI and cognitive abnormalities
- Neuropsychological impairment strongly correlated with severity of MRI white matter involvement ($p < .01$)



Toluene Leukoencephalopathy: A White Matter Dementia

- Toluene is a pure white matter toxin
- Myelin of the cerebral and cerebellar white matter is the major target of toluene, and gray matter is not involved
- White matter axons are affected only very late
- Dementia is the most notable feature, and its severity correlates with the degree of white matter damage
- Toluene leukoencephalopathy is the best example of white matter dementia



Spectrum of Toxic Leukoencephalopathy

	Mild	Moderate	Severe
Neurobehavioral Features	Confusion Inattention Forgetfulness Personality change	Somnolence Apathy Memory loss Dementia	Abulia Akinetic mutism Stupor Coma Death
MRI	Periventricular white matter hyperintensity	Diffuse white matter hyperintensity	Diffuse white matter hypodensity Necrotic areas
Neuropathology	Patchy intramyelinic edema and preserved myelin	Widespread edema with demyelination and preserved axons	Oligodendrocyte loss Axonal loss Necrosis

Gulf War Illness

(Research Advisory Committee Report, November 2008)

- 175,000-200,000 U.S. veterans of the 1990-1991 Gulf War were harmed by exposure to pyridostigmine and pesticides
- These exposures implicate neurotoxicity from carbamate and organophosphorus acetylcholinesterase inhibitors (AChEI)
- The prominence of memory loss, poor concentration, headache, and fatigue suggest that the brain is most involved
- Most affected veterans are not improving

What Is the Pathophysiology of Gulf War Illness?

- The answer remains unknown
- Basic studies using laboratory animals disclose AChEI-induced neuronal injury in neocortex, hippocampus, basal ganglia, and cerebellum - apoptosis? oxidative stress?
- Human studies have noted both gray and white matter changes in the brain
- Clinically, the question can be approached by epidemiology, neuropathology, neuropsychology, and neuroimaging

Epidemiology

- An excess of amyotrophic lateral sclerosis (ALS) has been found in Gulf War veterans (Haley, Neurology 2003; 61: 750-756) - is there a common toxic effect on neurons?
- A higher mortality from brain cancer has been found among veterans exposed in the 1991 Khamisiyah incident (Bullman et al., Am J Public Health 95:1382-1388) - since gliomas begin in the white matter (Stiles & Rowitch, Neuron 2008; 58: 832-846), is this a clue that AChEIs can induce white matter injury?

Neuropathology

- Very little information is available
- An autopsy case of sarin exposure after the Tokyo terrorist attack in 1995 (Himuro et al. Neurology 1998; 51: 1195-1197) documented distal axonopathy of myelinated fibers in peripheral nerves and the spinal cord, without demyelination, and only hypoxic-ischemic encephalopathy in the brain consistent with acute cardiopulmonary arrest; no specific toxic effect of sarin could be identified

Neuropathological Possibilities

- Gray matter damage may arise from primary neuronal cell body injury, and cause secondary white matter involvement via anterograde (Wallerian) degeneration
- White matter damage may arise from primary axonal, glial, or other injury, and cause secondary gray matter involvement via retrograde (dying back) degeneration
- Gray and white matter may be affected simultaneously

Neuropsychology

- The RAC Report summarized the existing data, concluding that differences in attention, executive function, memory, visuospatial skills, psychomotor speed, and mood and emotional function are most prominent
- Slowing of response speed affecting mental flexibility is evident across multiple domains
- These deficits closely match those reported in patients with a wide variety of white matter disorders

Neuroimaging: Basal Ganglia

- Haley et al. (Radiology 2000; 215: 807-817) used MRS to show reduced NAA in the basal ganglia and brainstem in Gulf War veterans (Cho was not elevated)
- Haley et al. (Arch Neurol 2000; 57: 1289-1285) found that as left basal ganglia functional neuronal mass (as measured by NAA) decreased, dopamine activity (as measured by plasma HVA/MHPG) increased

Neuroimaging: Hippocampus

- Menon et al. (Brain Res 2004; 1009: 189-194) used MRS to show that NAA was reduced in both hippocampi among Gulf War veterans
- Again, Cho was not elevated - this finding suggests that demyelination and inflammation are not neuropathological features

Neuroimaging: White Matter

- Heaton et al. (Neurotoxicology 2007; 28: 761-769) used volumetric MRI to show reduced cerebral white matter volume and enlarged lateral ventricles in Gulf War veterans potentially exposed to sarin and cyclosarin
- Yamasue et al. (Ann Neurol 2007; 61: 37-46) used VBM and DTI to show reduced peri-insular white matter volumes and decreased FA in widespread white matter areas of Tokyo victims exposed to sarin (note: reduced gray matter volume was also noted in right insula, right temporal cortex, and left hippocampus)

Summary

- White matter damage can produce major neurobehavioral sequelae, including dementia
- Toxic leukoencephalopathy is a common cause white matter dementia, and Gulf War Illness resembles this syndrome
- However, evidence exists for both white matter and gray matter damage in Gulf War Illness
- From what we now know, either gray or white matter may be primarily damaged and cause secondary effects on the other, or both may be affected simultaneously